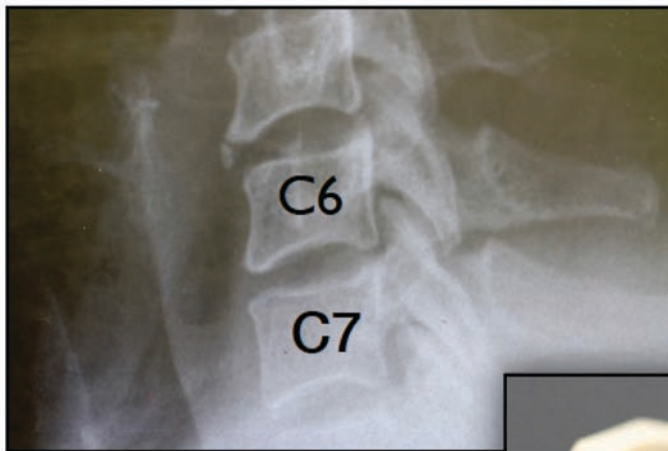
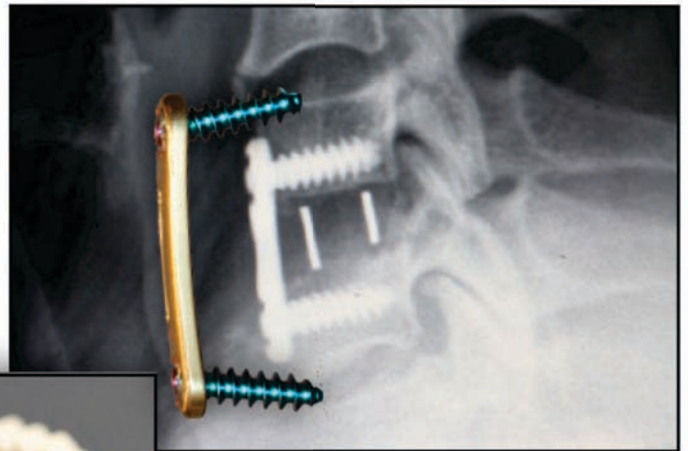


1 Level: C6/7

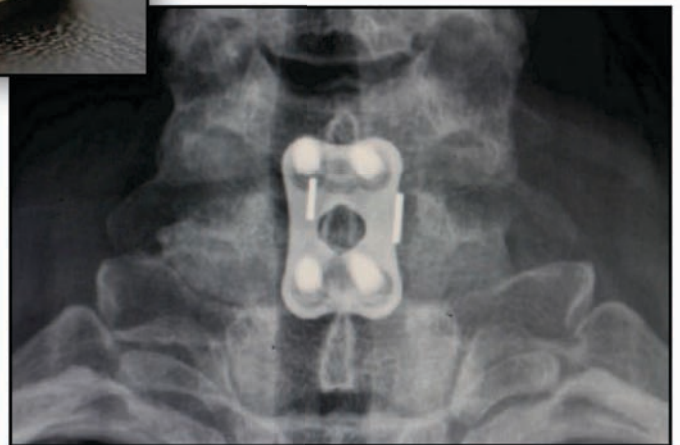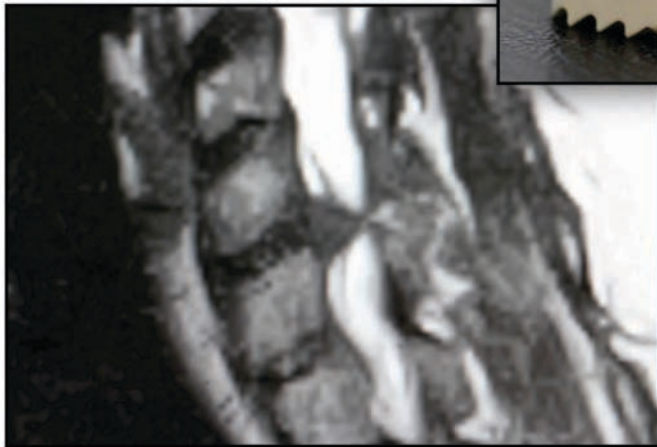

49 y/o WF with Radiculopathy & Triceps Weakness



Pre-Op

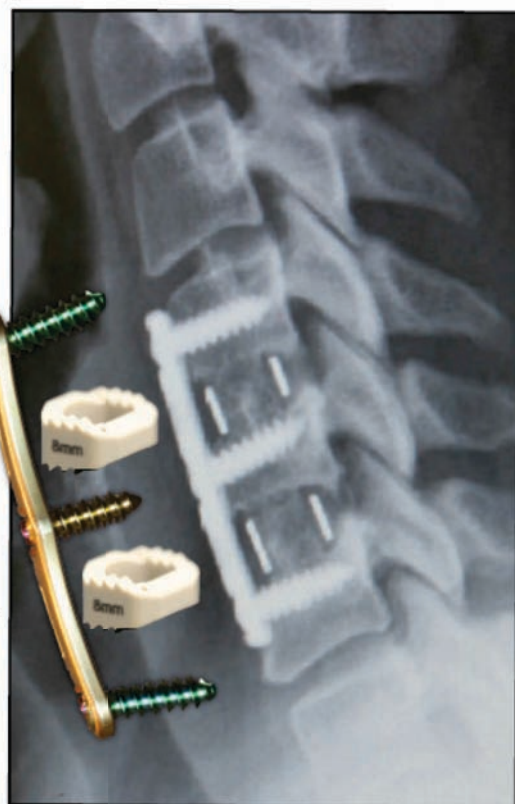
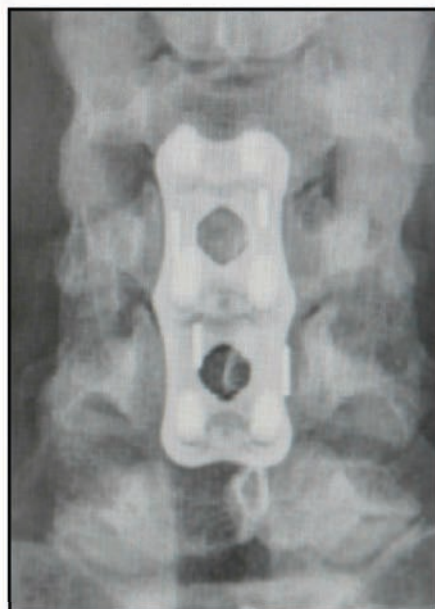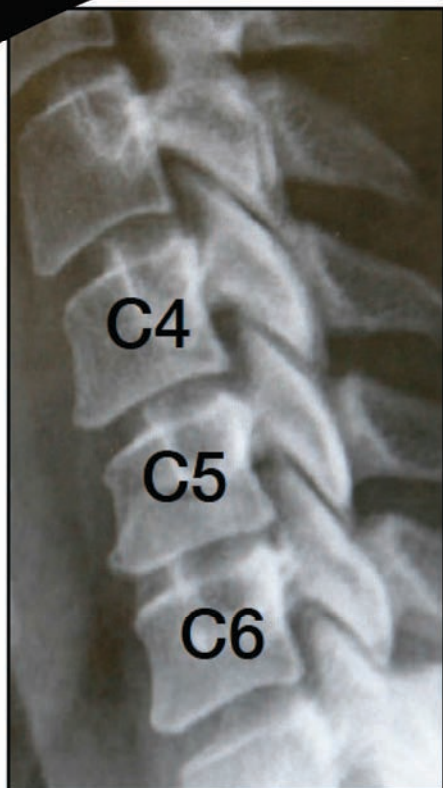


Post-Op



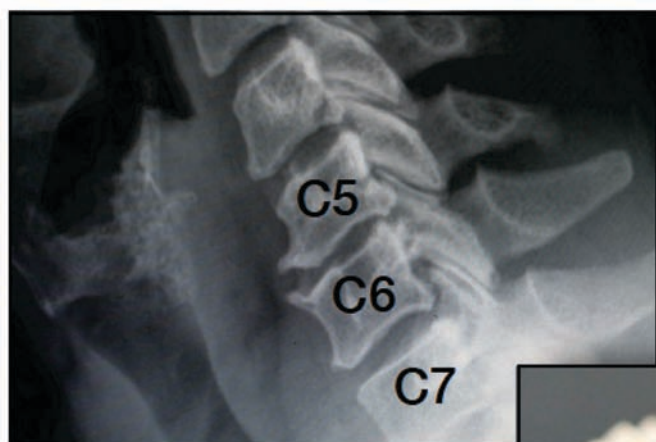
2 Level: C4/5 & C5/6

43 y/o WF with Disk Herniation & Biceps Weakness

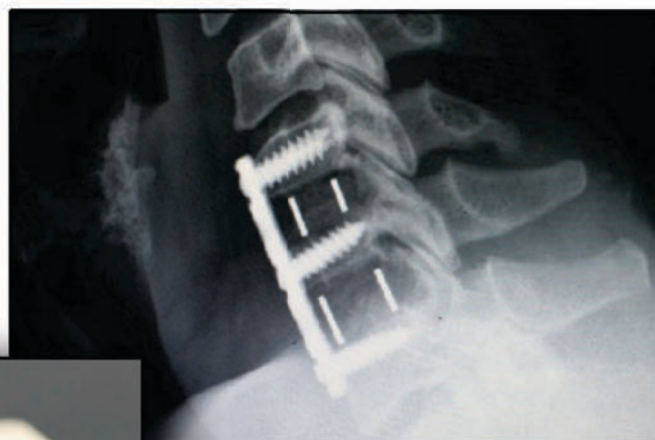

2 Level: C5/6 & C6/7

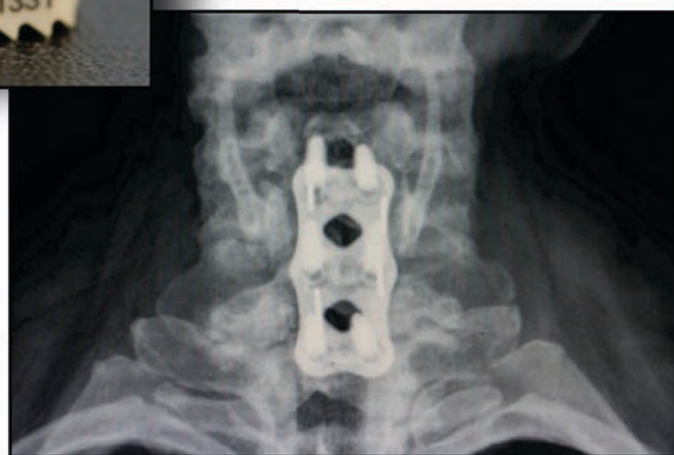
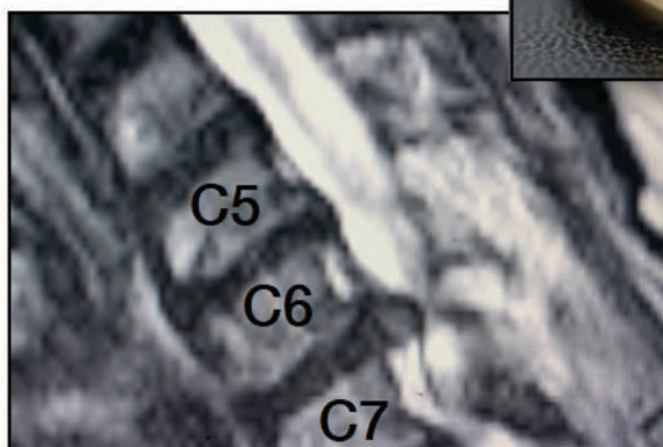

50 y/o WF with Severe Left Arm Radiculopathy & Triceps Weakness



Pre-Op

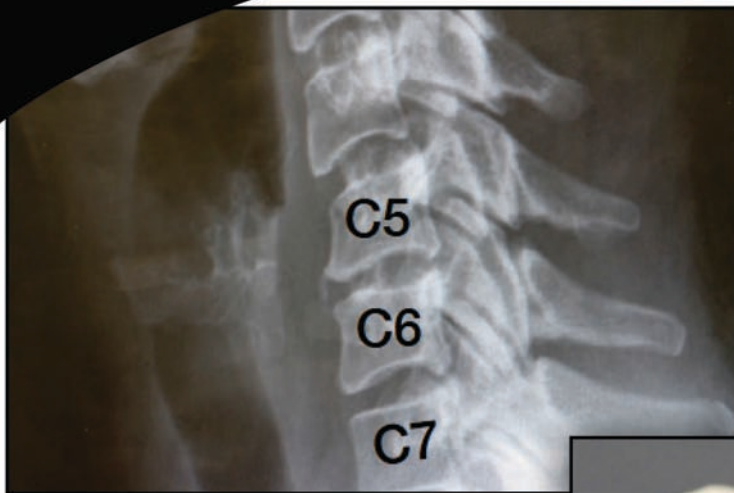


Post-Op

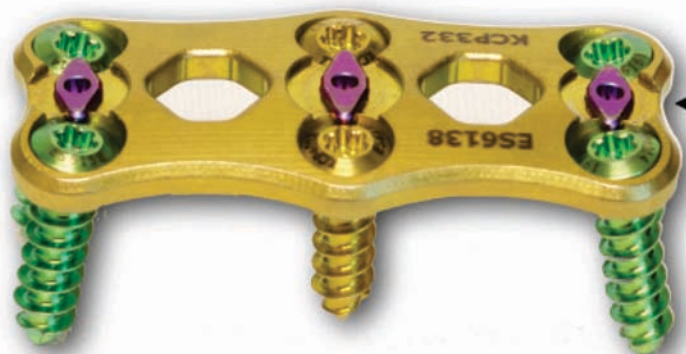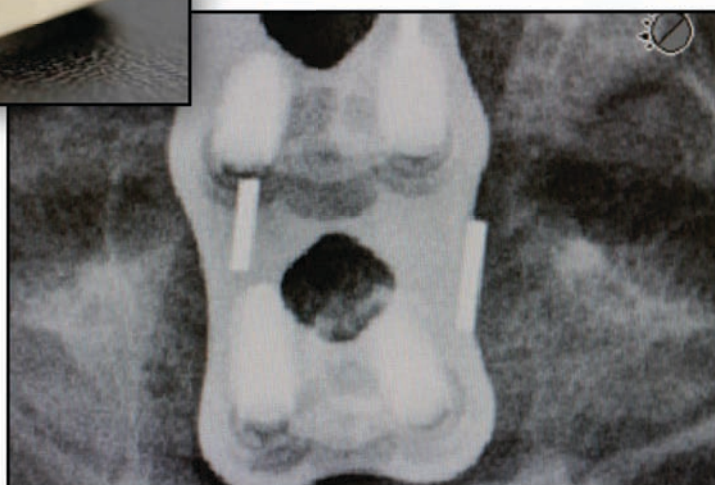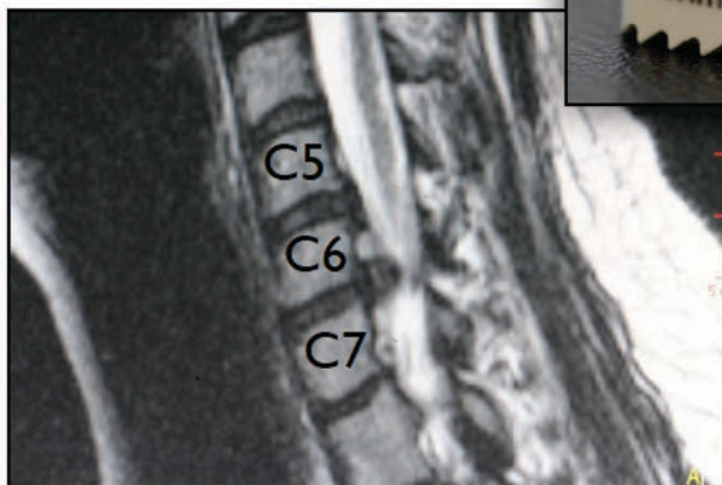


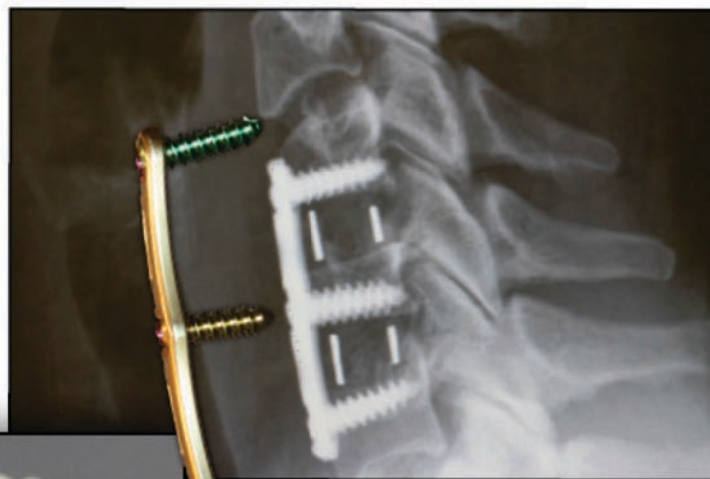
2 Level: C5/6 & C6/7

45 y/o WF with Severe Left Arm Radiculopathy & Triceps Weakness



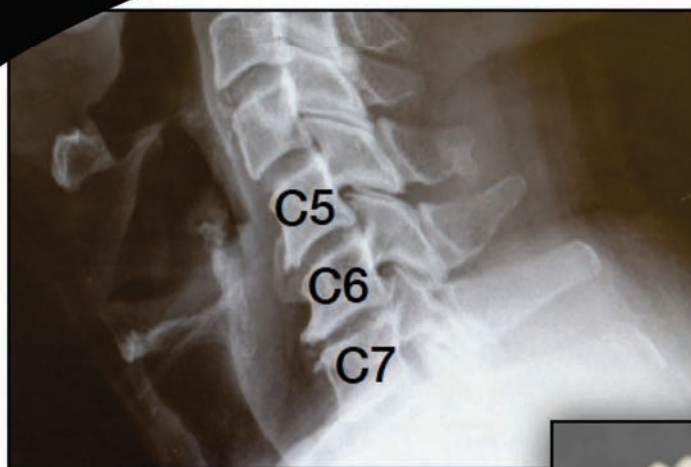Pre-Op



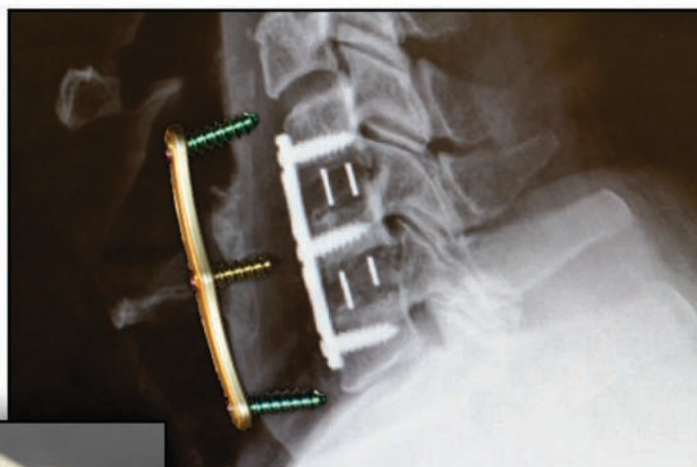Texas Twister

2 Level: C5/6 & C6/7

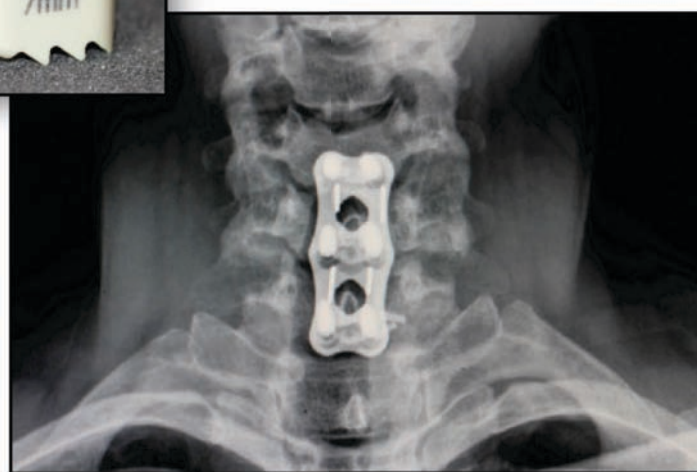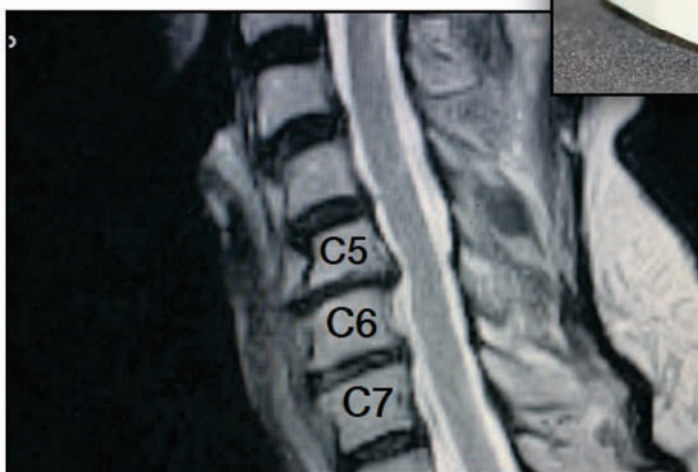
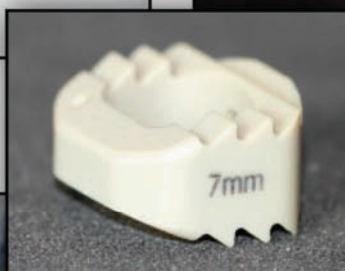64 y/o WM with CDD & Right Arm Radiculopathy



Pre-Op



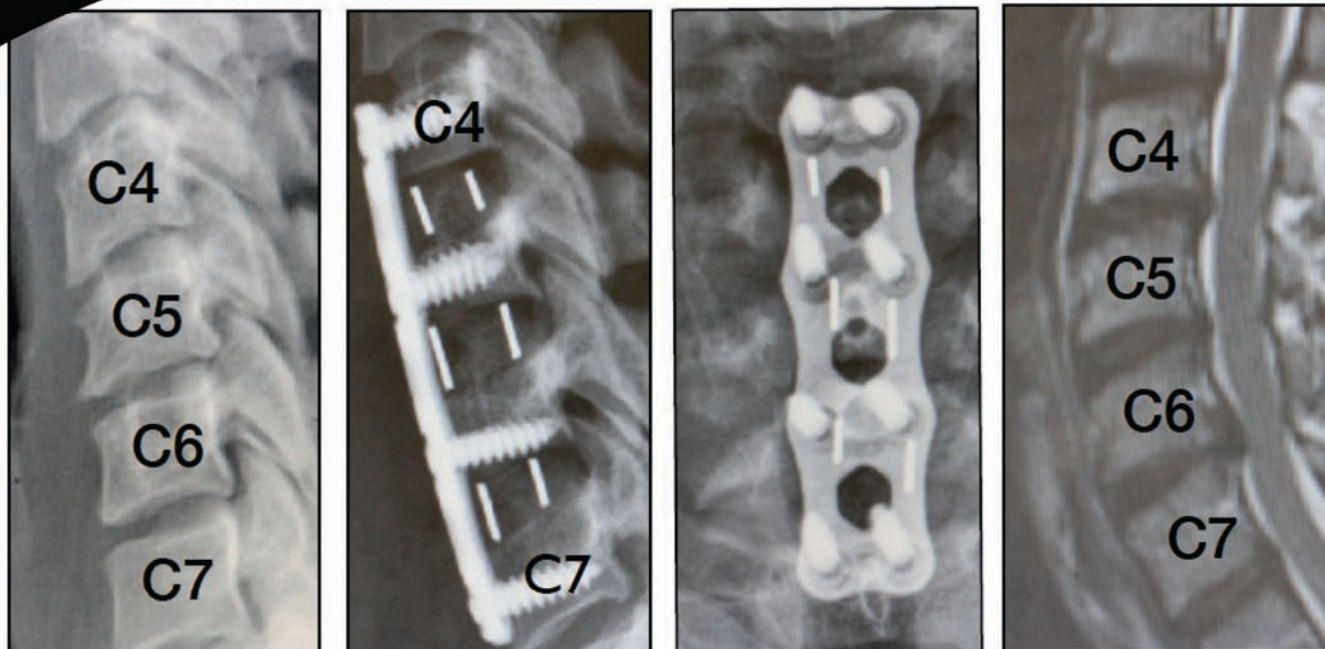
Post-Op



Updated 02/17/15

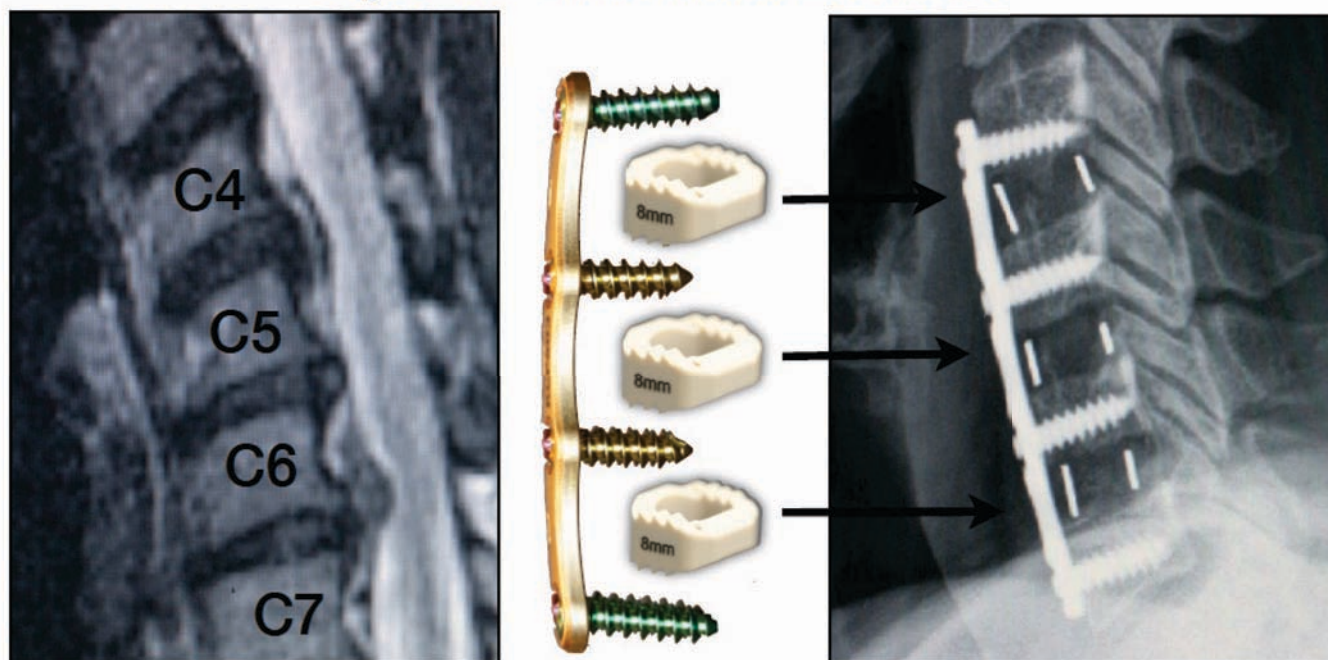
3 Level: C4/5, C5/6 & C6/7

37 y/o BF with Multi-Level Stenosis & Right Arm Radiculopathy



Pre-Op

*49y/o WF with Multi-Level Stenosis



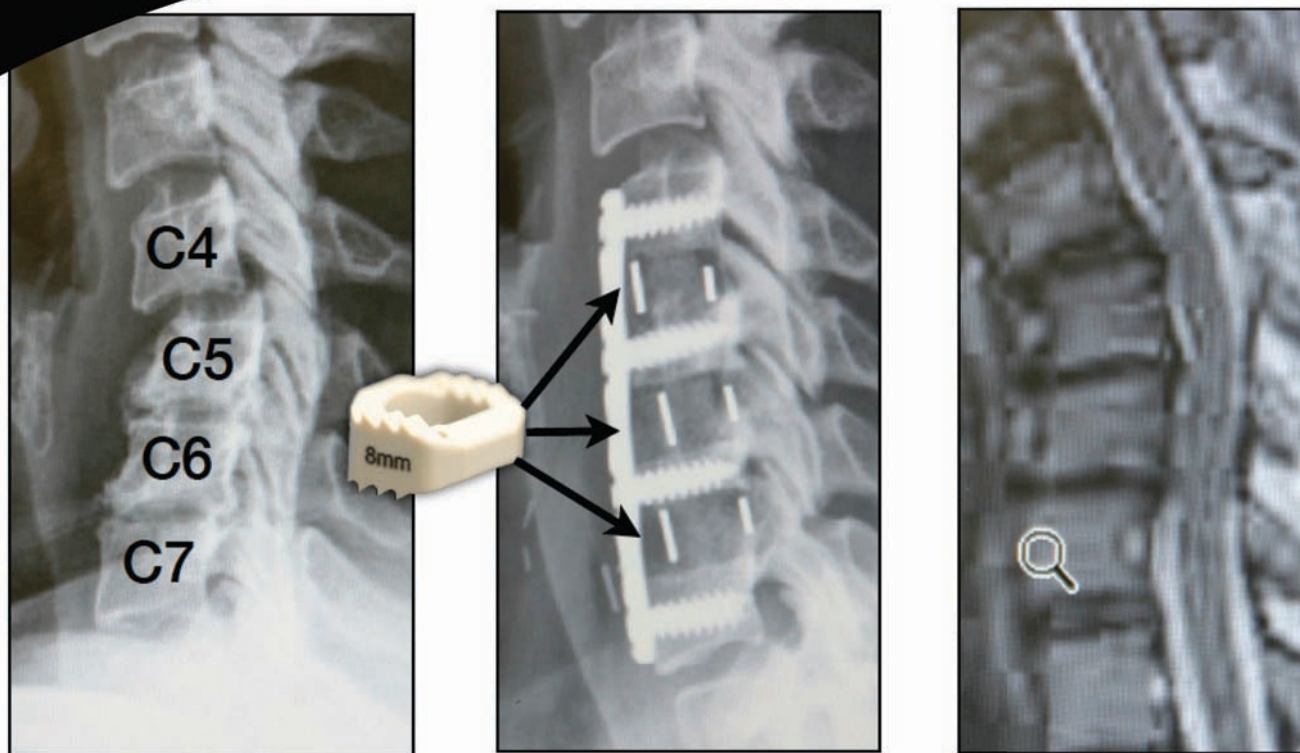
Pre-Op

Updated 02/17/15

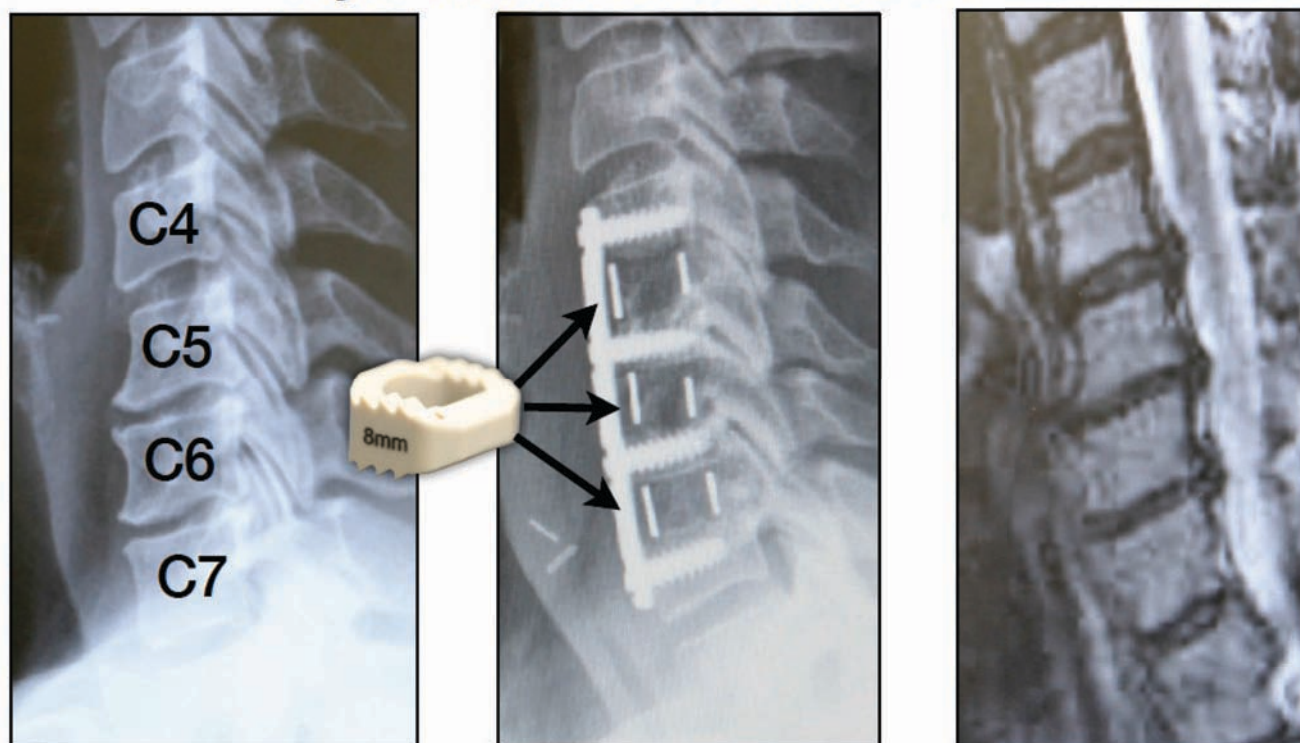
Post-Op

3 Level: C4/5, C5/6 & C6/7

61 y/o Multi-Level Stenosis C4-7

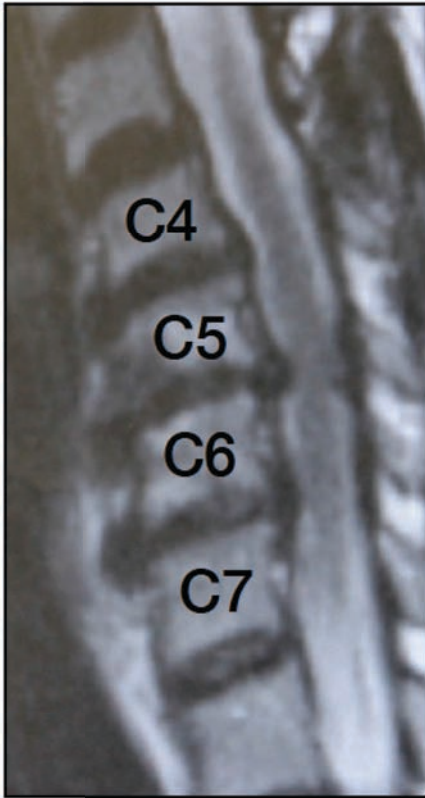
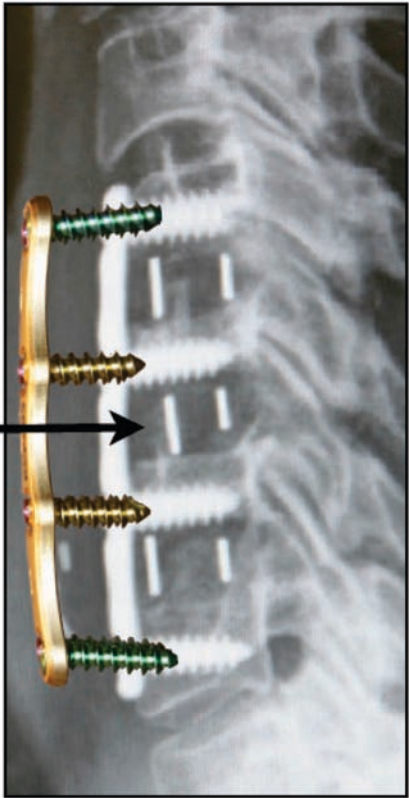
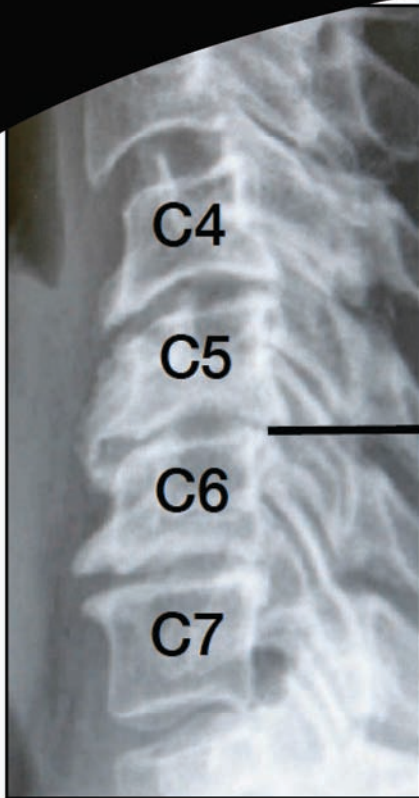


*59y/o Multi-level Stenosis C4-7

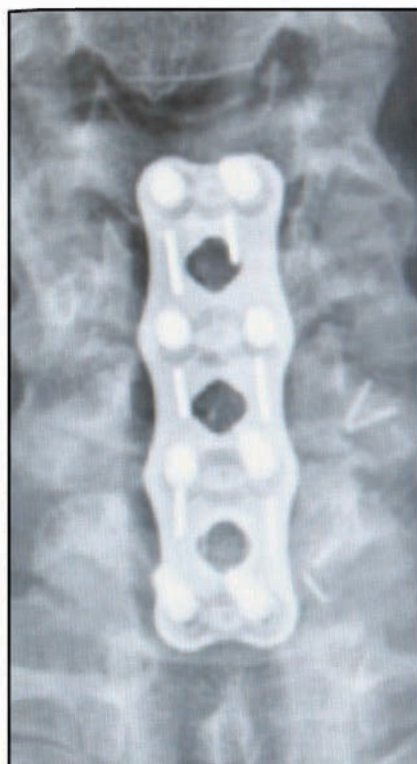
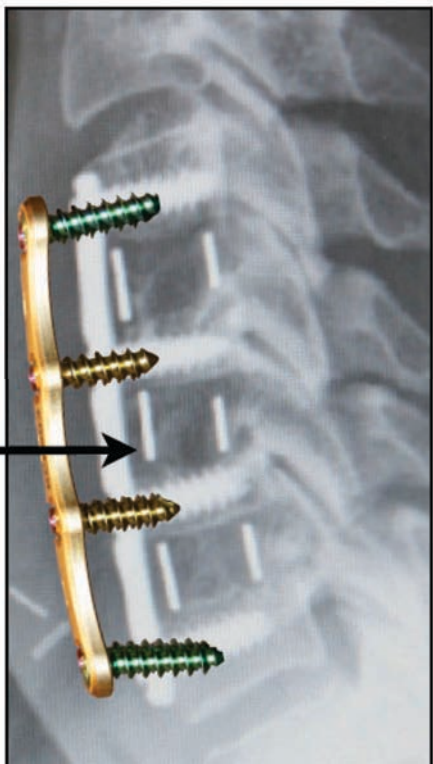
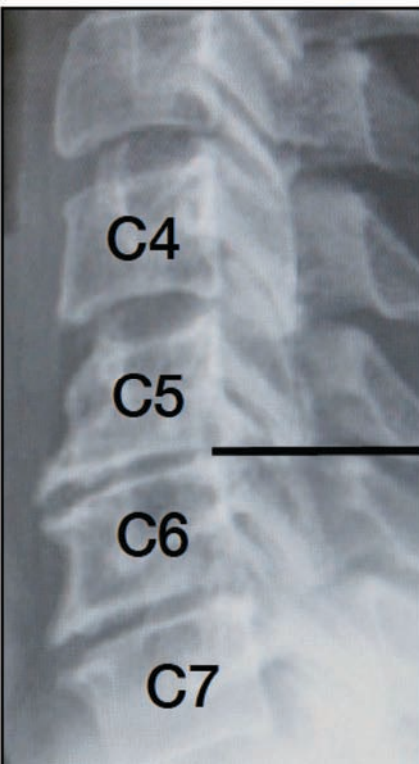


3 Level: C4/5, C5/6 & C6/7

66 y/o Multi-Level Stenosis C4-7

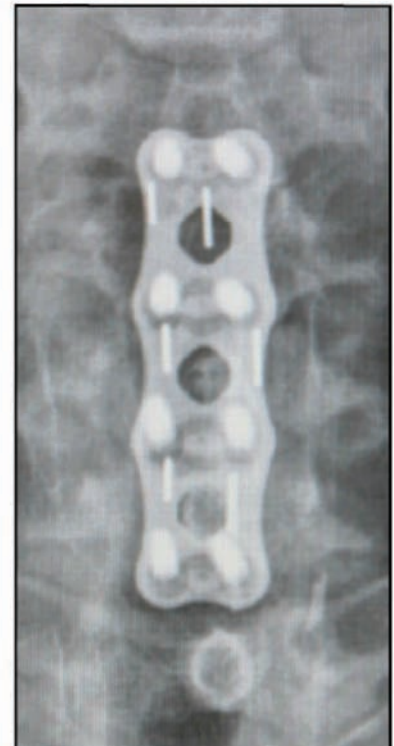
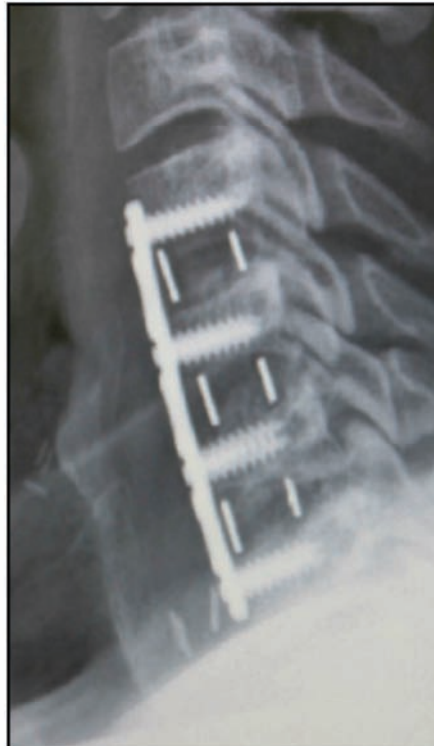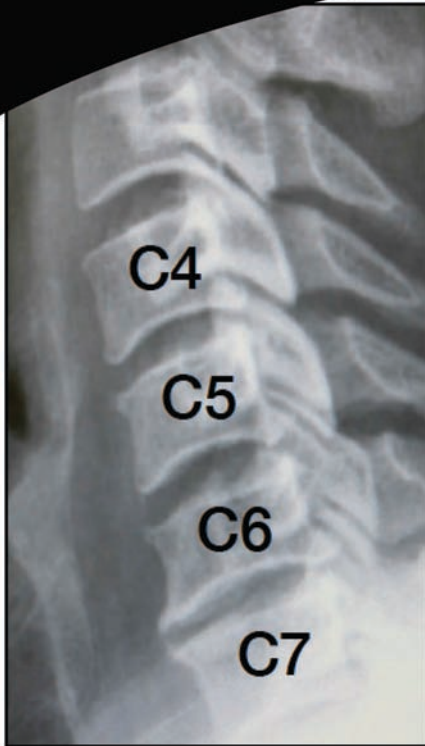


*62y/o Multi-level Stenosis C4-7

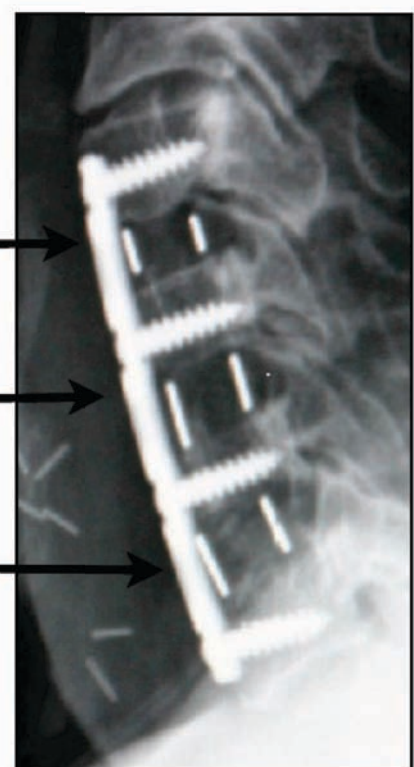
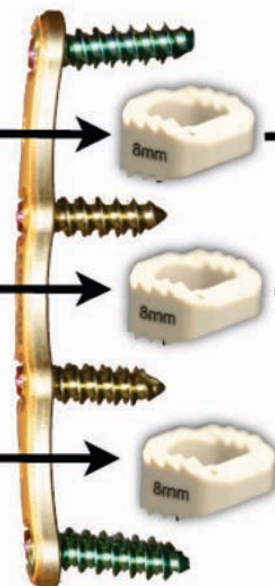
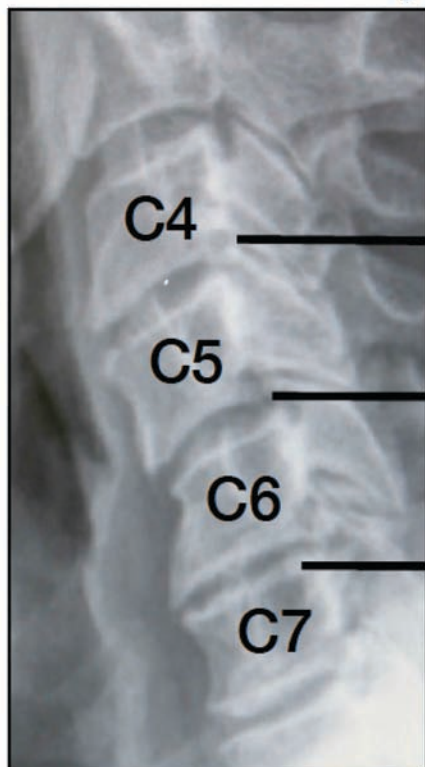


3 Level: C4/5, C5/6 & C6/7

48 y/o HNP & Stenosis C4-7

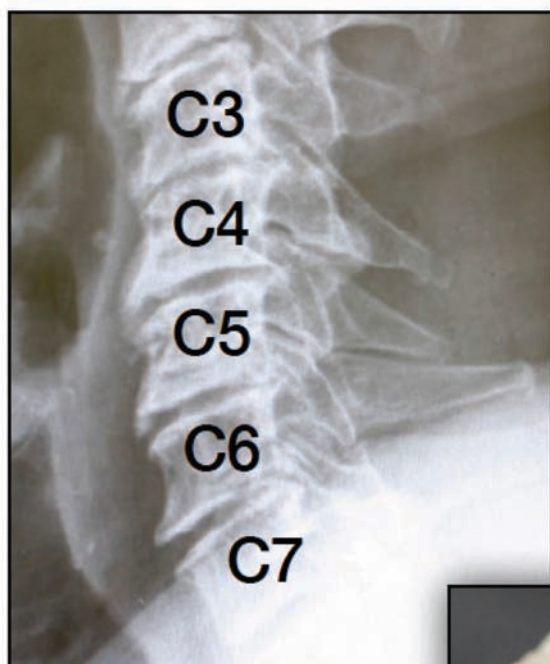


*45y/o HNP & Stenosis C4-7

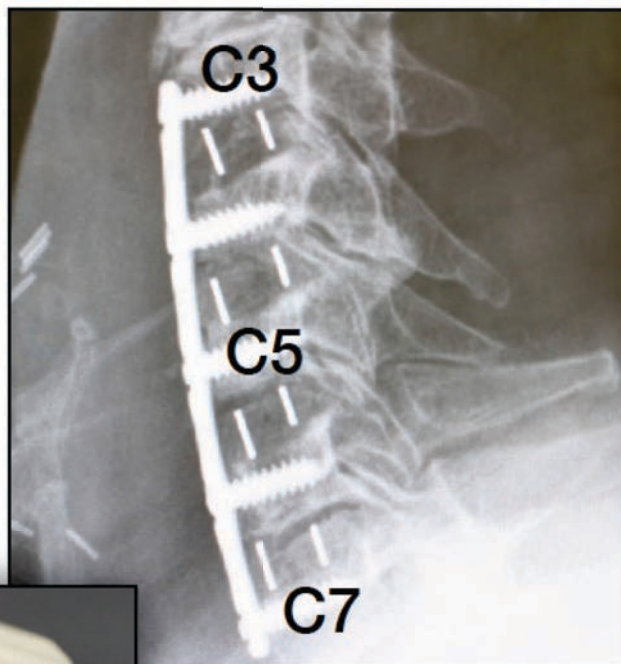


4 Level: C3/4, C4/5, C5/6 & C6/7

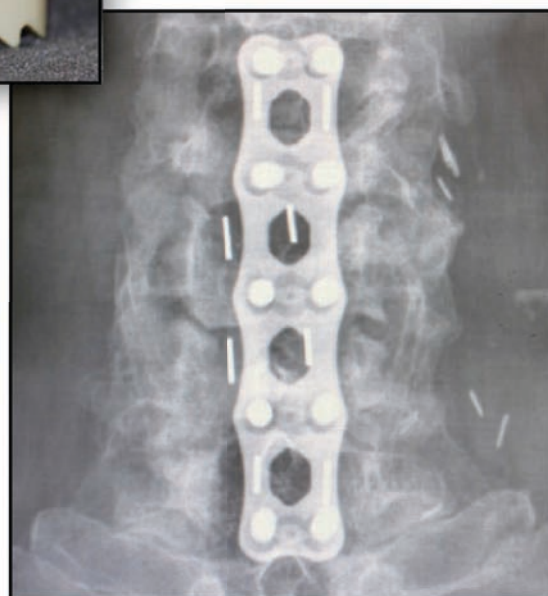
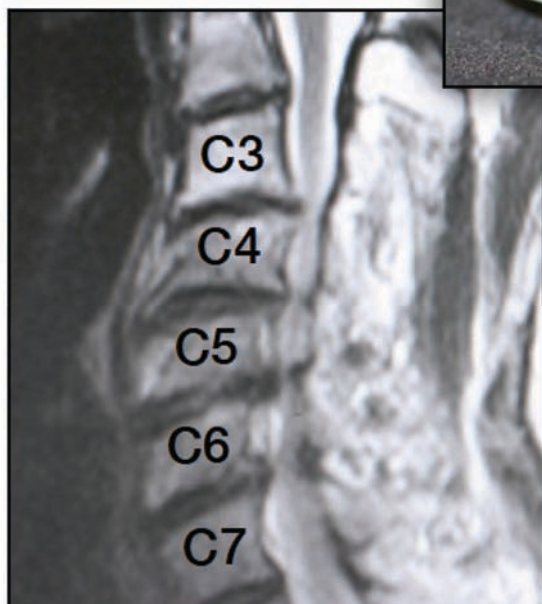
58 y/o WM with DDD & Multi-Level Stenosis



Pre-Op

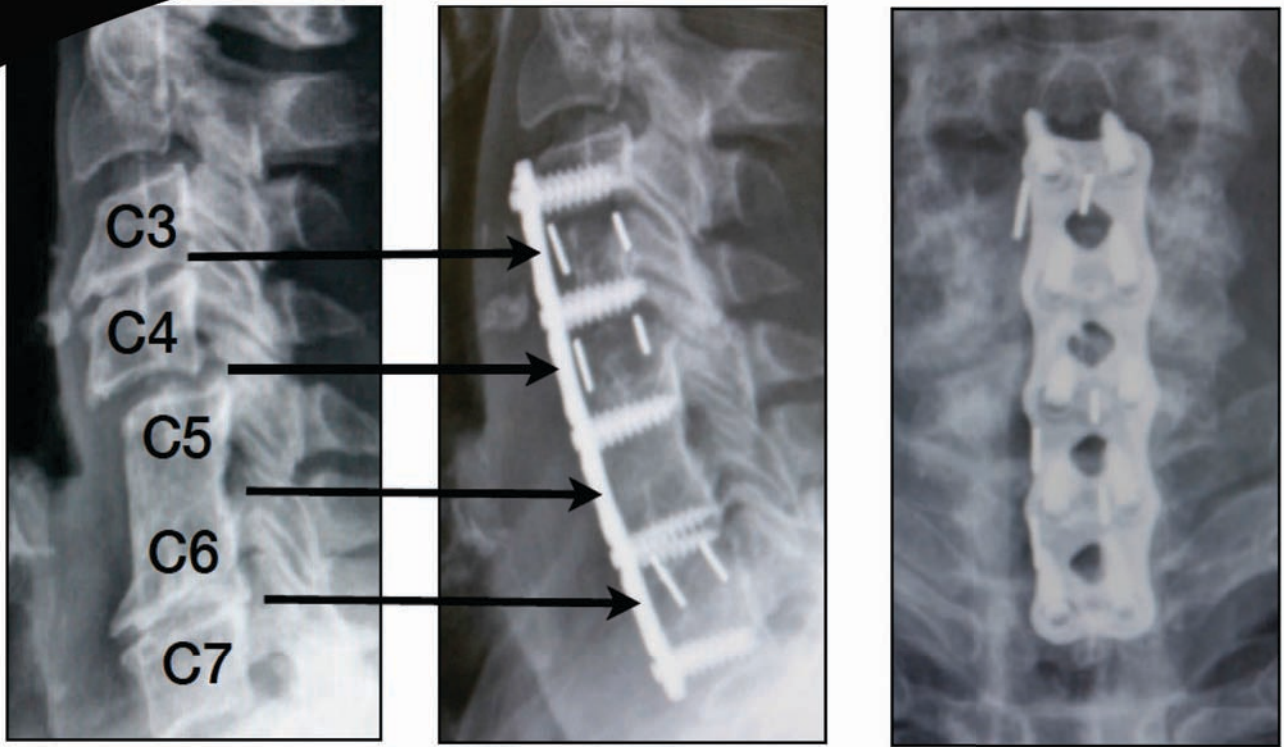


Post-Op

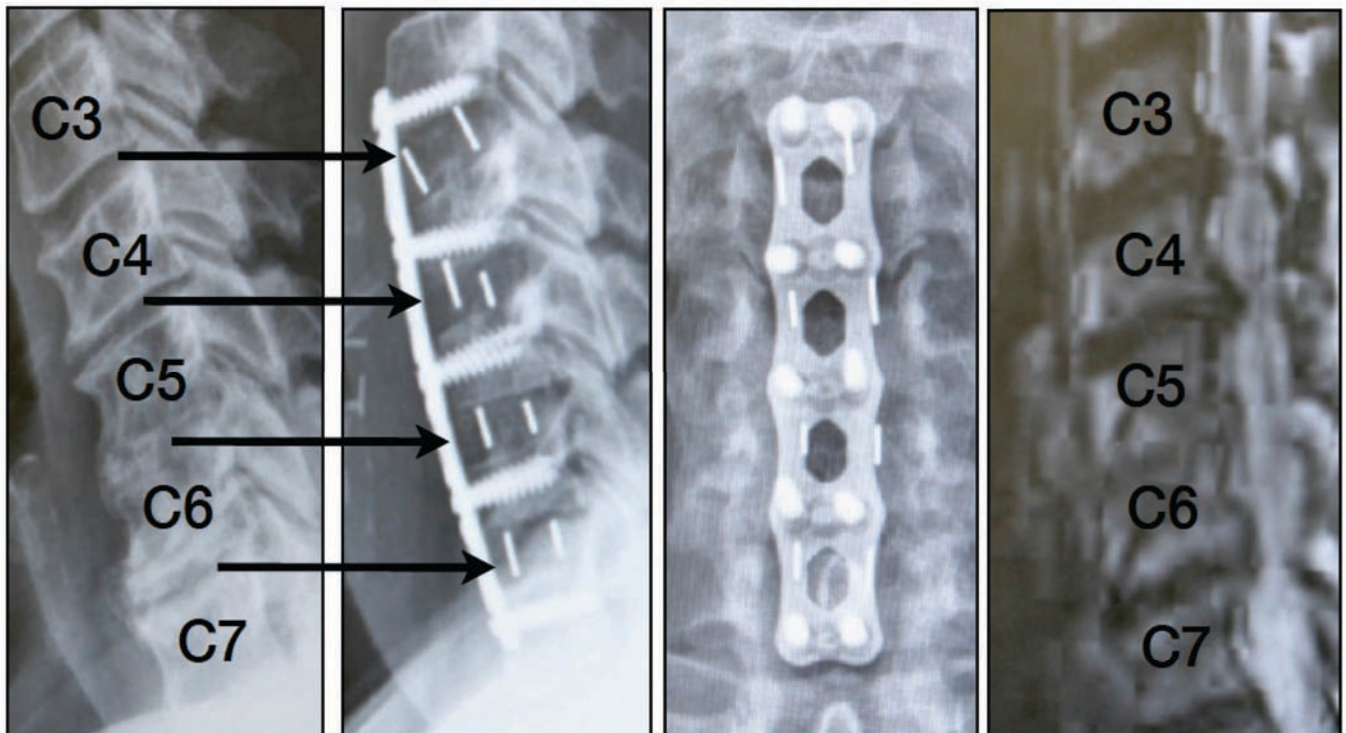


4 Level: C3/4, C4/5, C5/6 & C6/7

59 y/o with previous fusion C5/6

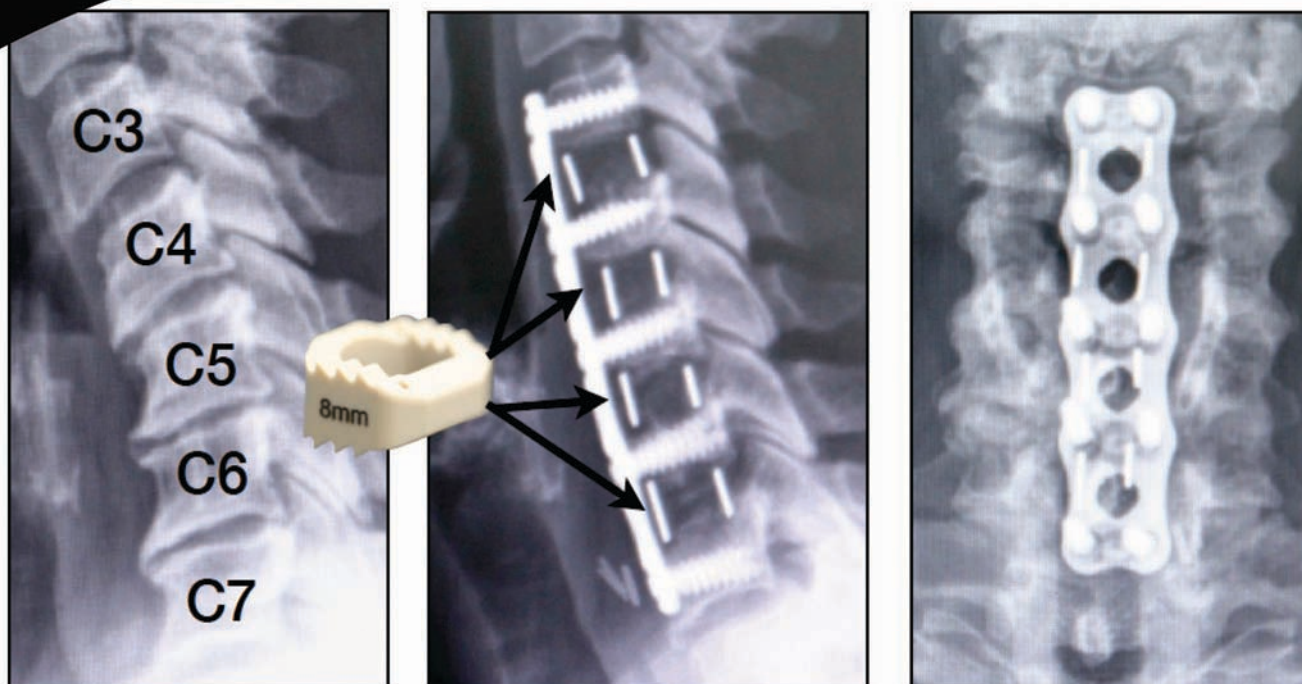


*63y/o Multi-level Stenosis

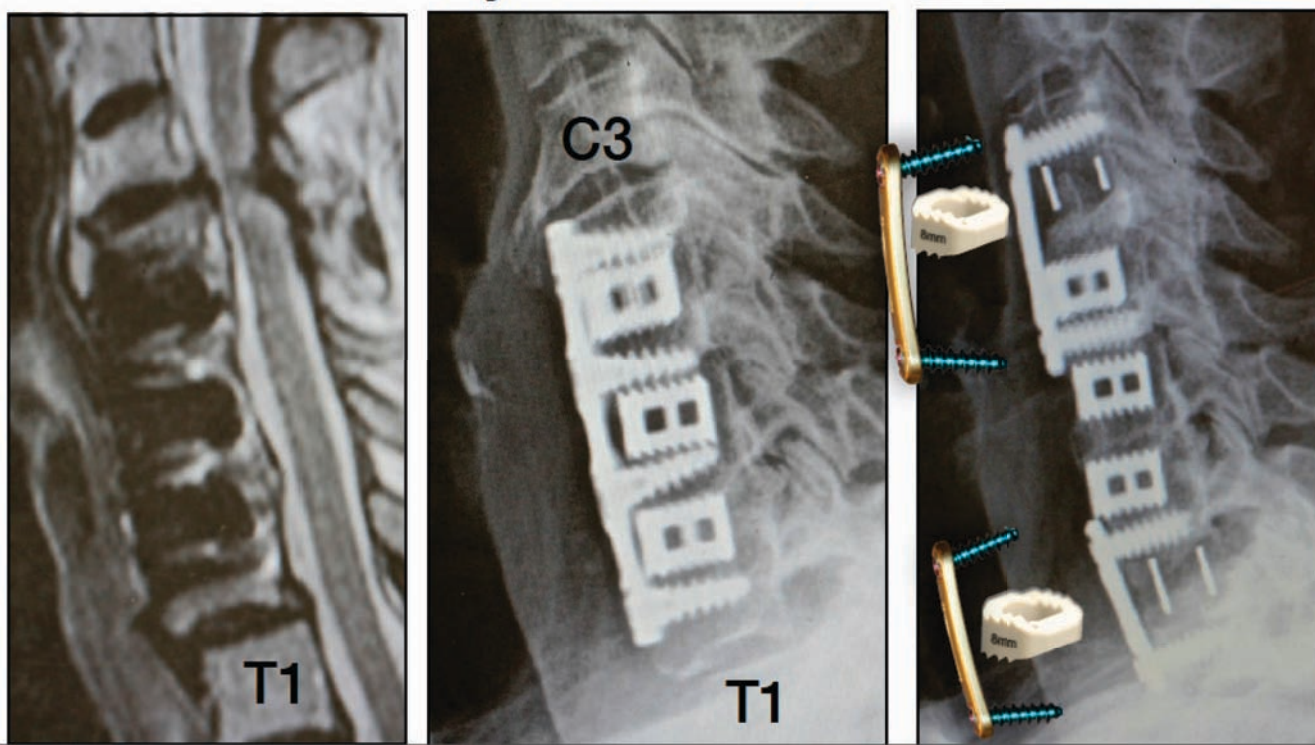


4 Level: C3/4, C4/5, C5/6 & C6/7

55 y/o with Degenerative Disk & Stenosis

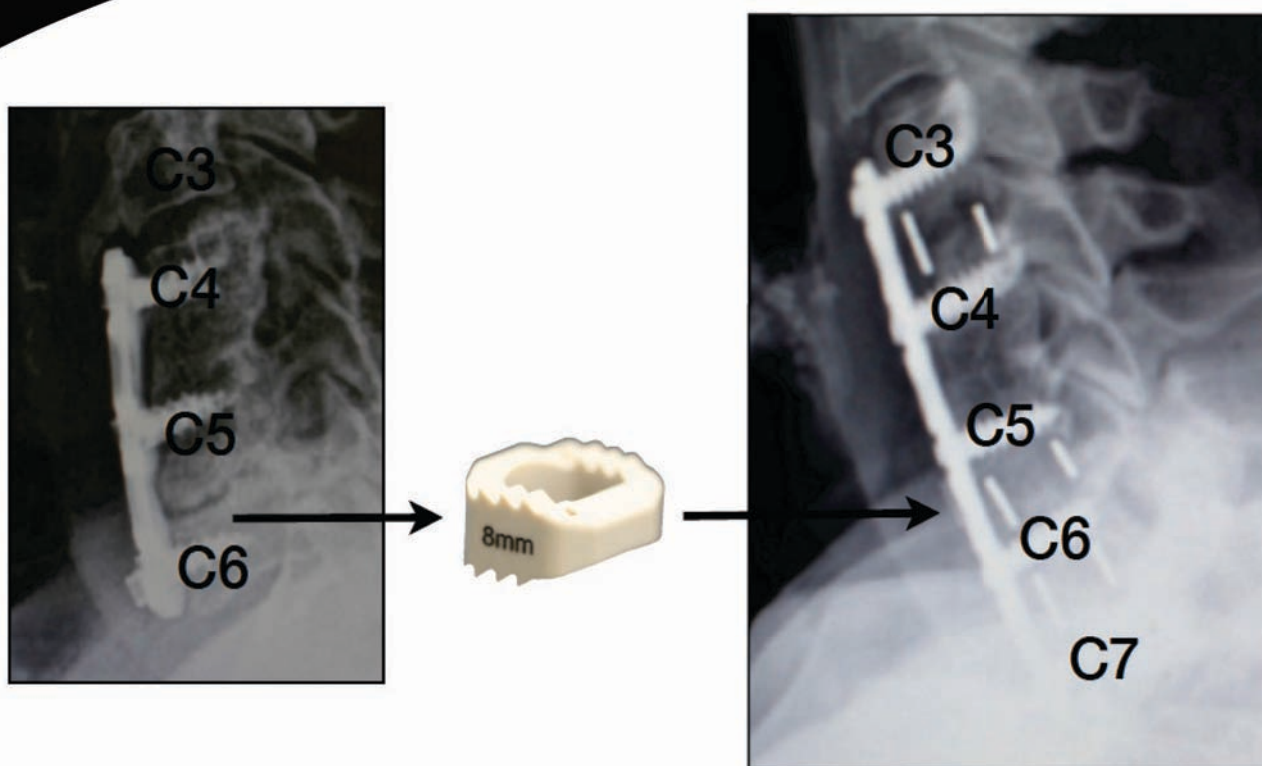


*68y/o C3-T1 Revision



4 Level: Revision

67 y/o with pseudoarthrosis & screw backing out



*64y/o with screw backing out C7

